The primary goals of endodontic treatment are straightforward: to debride and disinfect the root canal space to the greatest possible extent, and then seal the canals as effectively as possible.

The primary goals of restorative treatment are to restore teeth to function and comfort and in some cases, aesthetics. Once again, the materials and techniques change, but not the ultimate goals of treatment.
Data from 5O US states of the US on more than 1.4 million endodontic procedures delivered with 8-year follow—up shows how highly effective endodontic treatment is!
Survival of teeth was found to be 96%!
Prevention of reinfection through the oral cavity is a critical factor for endodontic treatment outcome. There are a number of studies which provide evidence for the importance of tight seal on endodontic treatment outcome.
There are several important considerations to take into account when planning RCT. Each of these play a critical role in the overall success of the procedure.

- Access Cavity —
- Preservation of Tooth Structure —
- Coronal Interim Restoration —
- Shaping —
- Irrigation / Dressings —
- Obturation —
- Restoration —

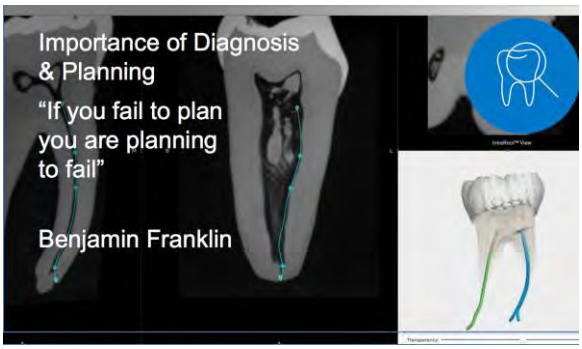

If an incorrect assessment is made, then improper management may result. This could include performing endodontic treatment when it is not needed or providing no treatment or some other therapy when root canal treatment is truly indicated.

It is not an uncommon practice to miss a canal while carrying out endodontic treatment especially in molar teeth where the 'one root = one canal' formula is frequently incorrect. A less—than—adequate access opening makes it difficult for the clinician to locate canals. The inability to treat ALL the canals is one of the leading causes of endodontic failures. The bacteria that remain in these canals lead to the persistence of symptoms.



The quotation in the image above is from John Ingle's textbook Endodontics. In full it reads: "The goal of hand and rotary instrumentation and irrigation is to remove all necrotic and vital organic tissue, as well as some hard tissue including dentin chips created by instrumentation, from the root canal system and give the canal system a shape that facilitates optimal irrigation. Debridement and placement of local medicaments, and permanent root filling. From a biological point of view, the goal of instrumentation and irrigation is to remove and eradicate the microorganisms residing in the necrotic root canal system. Furthermore, the goal is to neutralize any residual antigenic material remaining in the canal after instrumentation and irrigation."

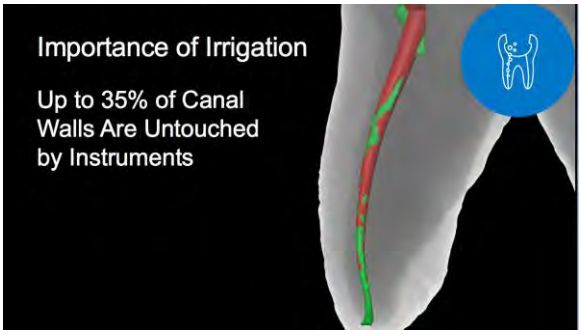

Research shows, regardless of the file system being used, up to 35% of the canal walls remain untouched by instruments. The root canal system must be thoroughly disinfected with irrigating solutions in order to achieve a successful outcome. The impact of not being thorough during the irrigation steps can be a negative one which can and will probably lead to case failures.

If the canal space is left empty between appointments, the remaining bacteria can multiply to nearly the original levels.

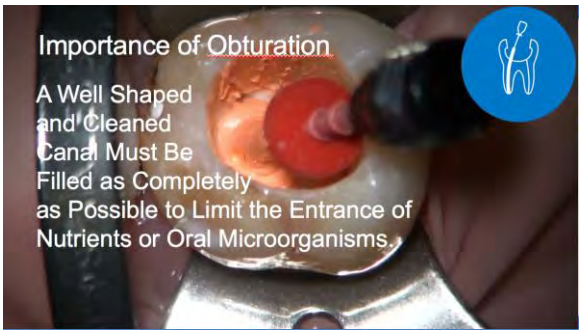

A well-shaped and cleaned canal system should create the best possible stage for the body's immune system to encourage healing. The space should be filled as completely as possible in order to limit the entrance of nutrients or oral microorganisms. While no established techniques for root canal filling create a perfect coronal, lateral and apical seal, many techniques offer high potential for success.

On top of the considerations which need to be taken around the basic endodontic procedure, several major factors around the restoration of the crown will determine the overall treatment outcome. The potential ingress of microbes into the canal system will compromise the outcome of endodontic treatment. Therefore, as was found by Trope, the overall success rate of endo will fall substantially if the restoration is delayed or poor.

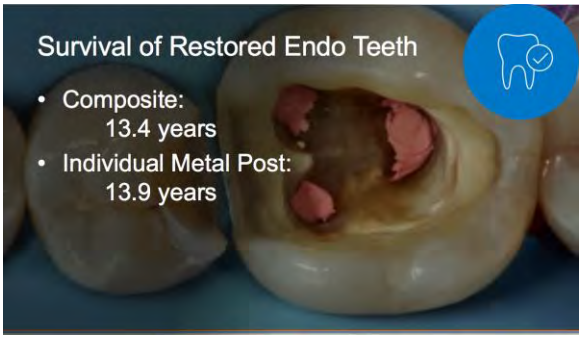

In a study by Dammaschke et al, the authors concluded that cavities with up to three surfaces may well be successfully restored adhesively with composite filling material.

Endodontically treated teeth restored with fiber posts were less prone to fracture than teeth restored with metal post. If teeth restored using a fiber post do fracture - the results of this study suggest — that the fracture will be minor enough to allow an additional attempt to repair the tooth.

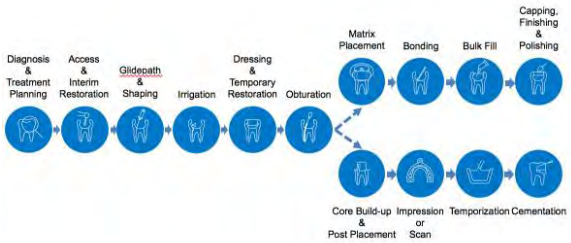

The icons represent key steps in endodontic and restorative treatment. The sequence is shown from left to right. From the time when a patient presents with a tooth which is diagnosed as needing RCT, right through the final finishing of the direct or indirect restoration.

REFERENCES:

Ree, Marga, and Richard S. Schwartz. "The endo-restorative interface: current concepts." Dental Clinics of North America 54.2 (2010): 345-374

Salehrabi, Robert, and Ilan Rotstein. "Endodontic treatment outcomes in a large patient population in the USA: an epidemiological study." Journal of endodontics 30.12 (2004): 846-850.

Elivas. 5.. J. Jalili, and N. Martin. "Restoration of the root canal treated tooth." British dental iournal 218.2 (2015): 53-62.

Schweitzer, J. L. "The endodontic diagnostic puzzle." General dentistry 57.6 (2008): 560-7.

Hoen, Michael M., and Frank E. Pink. "Contemporary endodontic retreatments: an analysis based on clinical treatment findings." Journal of endodontics 28.12 (2002): 834-836.

Wolcott, James, et al. "A 5 yr clinical investigation of second mesiobuccal canals in endodontically treated and retreated maxillary molars." Journal of endodontics 31.4 (2005): 262-264.

Tabassurn, Sadia, and Farhan Raza Khan. "Failure of endodontic treatment: The usual suspects." European journal of dentistry 10.1 (2016): 144.

Ingle's Endodontics. N.p.: Rmph USA, 2016.

Walla, Harmeet, William A. Brantley, and Harold Gerstein. "An initial investigation of the bending and torsional properties of Nitinol root canal files." Journal of endodontics 14.7 (1988): 346-351.

Thompson, S. A. "An overview of nickel—titanium alloys used in dentistry." International endodontic journal 33.4 (2000): 297-310.

Shen. Ya, et al. "Current challenges and concepts of the thermomechanical treatment of nickel-titanium instruments." Journal of endodontics 39.2 (2013): 163-172.

Peters, O. A.. et al. "Determining cutting efficiency of nickel-titanium coronal flaring instruments used in lateral action." International endodontic journal 47.6 (2014): 505-513.

Peters, O. A., K. Schonenberger, and A. Laib. "Effects of four Ni—Ti preparation techniques on root canal geometry assessed by micro computed tomography." international endodontic iournal 34.3 (2001): 221-230.

Ghoddusi, J., Javidi, M., Zarrabi, M. H., & Bagheri, H.. "Flare-ups incidence and severity after using calcium hydroxide as an intra canal dressing." Iranian Endodontic Journal 1.1 (2010): 7-13.

Schafer, Edgar, et al. "Percentage of Gutta—percha Filled Areas in Canals Obturated with Cross-linked Gutta-percha Core-carrier Systems, Single-Cone and Lateral Compaction Technique." Journal of endodontics 42.2 (2016): 294-298.

REFERENCES

Gabardo, Marilisa Carneiro Leéo, et al. "Effectiveness of different obturation techniques in surpassing the ledge formed in simulated curved canals." Brazilian Journal of Oral Sciences 12.2 (2013): 138-142.

Marques-Ferreira, Manuel, et al. "Sealing efficacy of system B versus Thermafil and Guttacore obturation techniques evidenced by scintigraphic analysis." Journal of clinical and experimental dentistry 9.1 (2017): e56.

Li, Guo-hua, et al. "Quality of obturation achieved by an endodontic core-carrier system with crosslinked gutta-percha carrier in single-rooted canals." Journal of dentistry 42.9 (2014): 1124-1134.

Abarca. Ana Maria, Antonieta Bustos, and Marcelo Navia. "A comparison of apical sealing and extrusion between Thermafil and lateral condensation techniques." Journal of endodontics 27.11 (2001): 670-672.

Saunders, W. P., and E. M. Saunders. "Coronal leakage as a cause of failure in root-canal therapy: a review." Dental Traumatology 10.3 (1994): 105-108.

Vire, Donald E. "Failure of endodontically treated teeth: classification and evaluation." Journal of endodontics 17.7 (1991): 338-342.

Ray. H. A.. and M. Trope. "Periapical status of endodontically treated teeth in relation to the technical quality of the root filling and the coronal restoration." International enclodontic iournal 28.1 (1995): 12-18.

Siogren, U. L. F., et al. "Factors affecting the long-term results of endoclontic treatment." Journal of endodontics 16.10 (1990): 498-504.

Dammaschke, Till, et al. "Influence of coronal restorations on the fracture resistance of root canal-treated premolar and molar teeth: A retrospective study." Australian Endodontic Journal 39.2 (2013): 48-56.

Diagnosis and Treatment Planning

The standard diagnostic framework in use today is the SOAP format.

Subjective information is the patient's chief complaint and a history.
Objective Findings are observed conditions in the area and the results of clinical testing.
Assessment is the diagnosis made, and Plan of treatment can only happen after the other steps have been completed.

The clinical exam should always include documentation of everything of relevance (remembering however that seemingly irrelevant findings may prove to be the most significant in the long run. This is why insurance carriers insist on documenting everything.).
During the visual examination, the clinician is looking for areas of swelling, asymmetry, discoloration, and anything else that appears to not be Within Normal Limits (WNL).
Palpation is performed to detect periapical inflammation that has spread to the surface mucosa and may indicate an underlying endodontic problem.
Periodontal probing is mandatory and some locations even require it's use. It is critically important and should not be overlooked!

Diagnosis and Treatment Planning

When exposing radiographs, whether digital or film, some form of positioning device is indicated if it is at all possible to use one.

The radiographic angulations are much more reproducible and diagnostic for endodontic purposes when compared to the bisecting angle technique.

Technology has improved with digital sensors in the last few years.
Some of the advantages of newer digital sensors include the following:

- Different sizes of sensors for different patients.
- Digitally resizing images aids during diagnosis.
- Tougher plastic bodies hold up better in day-to-day use
- Sensors with rounded corners and edges are more comfortable for the patient.

Use of CBCT imagery for endodontic diagnosis is growing. It can be useful when there is unusual periapical pathology, complex anatomy, trauma or potential root fractures.

Diagnosis and Treatment Planning

The ability to interpret CBCT information is often a function of the software being used.

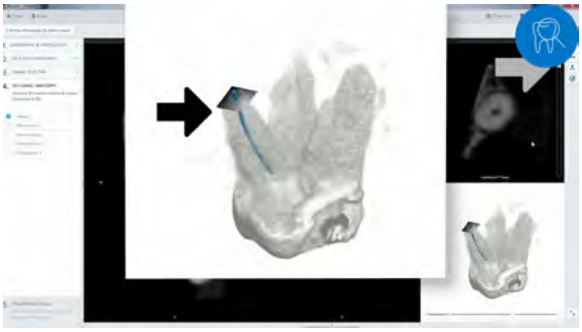

3D Endo software was specifically developed to provide new views that can be particularly helpful for endodontic diagnosis and treatment planning.

There are three categories of assessment that must be designated. Pulpal diagnosis and periradicular (periapical) status are the expected. The clinician must also rule out or rule in non-endodontic factors.

Treatment planning is generally straightforward once the correct diagnosis has been made. There are three possibilities when it concerns the endo:
Endodontic therapy (to be done in almost all cases if the tooth is restorable)
Extraction (if the tooth is not predictably restorable)
Referral (if the case is challenging)
At the same time, consideration should be given to the restoration of the tooth. Either a direct restoration (Class Two) or in-direct restoration where a core and post are placed with the intention of placing an eventual crown should be part of the plan.

Diagnosis and Treatment Planning

Once you have made your diagnosis and determined RCT is the treatment you can plan your access.

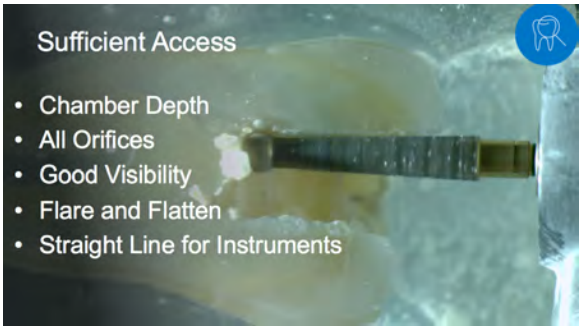

A few critical points for access must be considered when planning the case.
Understanding the depth of the pulp chamber is critical to avoid iatrogenic issues.
The clinician must determine the best approach which will allow entrance into all the orifices.
The access cavity must provide for good visibility to each of the orifices
Flaring and flattening of the chamber walls is helpful in creating a good reservoir for irrigating solutions.
Finally, and most importantly, the access chamber must be sufficiently large to allow for straight-line entrance of instruments into the canals.

A number of factors must be considered when planning for the eventual restoration of the endodontically treated tooth.

Diagnosis and Treatment Planning

For many patients the primary issue will be the cost. Financial considerations should be discussed honestly and completely with the patient. The risk factors associated with some restorative options must be fully understood as well. It should be noted that some research suggests that up to 85% of endodontic failures are tied directly to the failure to get full cuspal coverage.

It should also be noted that time management is another reason often used to avoid an indirect restoration.

Patient compliance must be considered when there is a likelihood that the patient may not return for additional restorative work.

When planning the case treatment, consideration must be given to the vitality of the tooth relative to its restorability.

Another decision point for the clinician will be around whether the case will be treated in one visit or two.

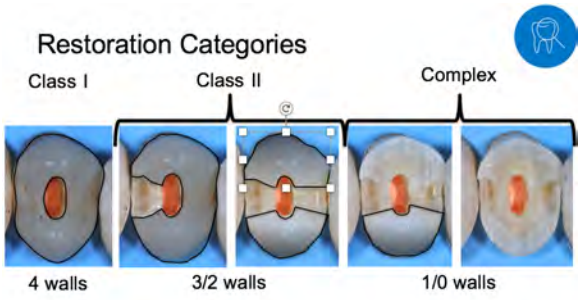

The proper treatment plan includes taking into account the eventual restoration based in part on the remaining tooth structure.

Post placement should also be determined on a case-by-case basis. The need for a post can impact the method of obturation to be employed.

REFERENCES:

Gutmann, James L., and Paul E. Lovdahl. Chapter 1. Problem Solving in Endodontics: Prevention, Identification, and Management. 5th ed. St. Louis: Elsevier, 2011.

Newton, Carl W., et al. "Identify and determine the metrics, hierarchy, and predictive value of all the parameters and/or methods used during endodontic diagnosis." Journal of endodontics 35.12 (2009): 1635-1644.

Levin, Linda G., et al. "Identify and define all diagnostic terms for pulpal health and disease states." Journal of endodontics 35.12 (2009): 1645-1657.

Gutmann, James L., et al. "Identify and define all diagnostic terms for periapical/periradicular health and disease states." Journal of endodontics 35.12 (2009): 1658-1674.

Salehrabi, Robert, and Ilan Rotstein. "Endodontic treatment outcomes in a large patient population in the USA: an epidemiological study." Journal of Endodontics 30.12 (2004): 846-850.

Plotino, Gianluca, et al. "Fracture resistance of endodontically treated molars restored with extensive composite resin restorations." The Journal of prosthetic dentistry 99.3 (2008): 225-232.

Pratt, Isaac, et al. "Eight-Year Retrospective Study of the Critical Time Lapse between Root Canal Completion and Crown Placement: Its Influence on the Survival of Endodontically Treated Teeth." Journal of Endodontics 42.11 (2016): 1598-1603.

Dammaschke, Till, et al. "Influence of coronal restorations on the fracture resistance of root canal-treated premolar and molar teeth: A retrospective study." Australian Endodontic Journal 39.2 (2013): 48-56.

Soares, Paulo Vinicius, et al. "Influence of restorative technique on the biomechanical behavior of endodontically treated maxillary premolars. Part I: fracture resistance and fracture mode." The Journal of prosthetic dentistry 99.1 (2008): 30-37.

Friedman S, Mor C. The success of endodontic therapy--healing and functionality. J Calif Dent Assoc. 2004;32:493-503.

Ferrari, M., et al. "Collagen degradation in endodontically treated teeth after clinical function." *Journal of dental research* 83.5 (2004): 414-419.

Sathorn, C., P. Parashos, and H. H. Messer. "Effectiveness of single-versus multiple-visit endodontic treatment of teeth with apical periodontitis: a systematic review and meta-analysis." International endodontic journal 38.6 (2005): 347-355.

Figini, Lara, et al. "Single versus multiple visits for endodontic treatment of permanent teeth: a Cochrane systematic review." Journal of endodontics 34.9 (2008): 1041-1047.

Aurélio, I. L., Fraga, S., Rippe, M. P., & Valandro, L. F. "Are posts necessary for the restoration of root filled teeth with limited tissue loss? A structured review of laboratory and clinical studies." International endodontic journal (2015).

When there is a deep understanding of and respect for the anatomic complexity of the teeth, then the astute clinician can use all of the available techniques and instruments in endodontics to achieve the aims of canal instrumentation, disinfection, and obturation which should lead to the highest possibility of success in root canal therapy.

Understanding Canal Morphology Ensures All Systems Are Addressed.

Conversely, if the clinician does not appreciate the complexity and nuance of the anatomy of a tooth and does not take this into account when performing endodontic therapy, poorer outcomes will result.

- Facilitate introduction of endodontic instruments into the radicular pulp.
- Permit removal of the entire chamber contents.
- Enable complete, direct vision of the pulp chamber floor and the orifices
- Provide straight-line access

Access

Badly broken-down teeth provide a challenge in canal isolation and temporization. Without four walls, the access preparation cannot retain irrigating solutions during instrumentation and badly broken-down teeth are difficult to seal with a dental dam

The rubber dam is considered a critical piece of successful endodontic therapy. The reasons for using the rubber dam include:

- Creating and maintaining a clean field for the procedure.
- Protecting the patient from aspirating or ingesting small instruments.
- Retracting of surrounding tissue.
- Clear visibility of the area being treated.
- Protecting the clinician and assistants from disease causing agents which could be spread by the patient's saliva.

The coronal pulp of the young tooth extends far incisally and has 3 pulp horns in central incisors and 2 in lateral incisors. Initial penetration should be in the middle of the tooth both inciso-gingivally and mesio-distally.

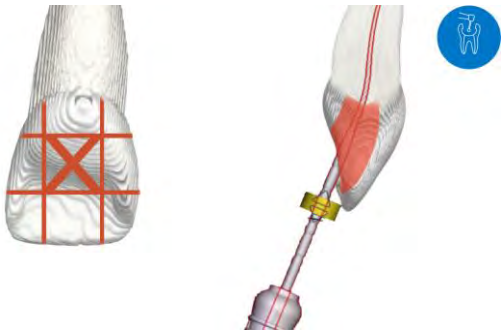

With posterior teeth the access must be large enough to see each of the canals.

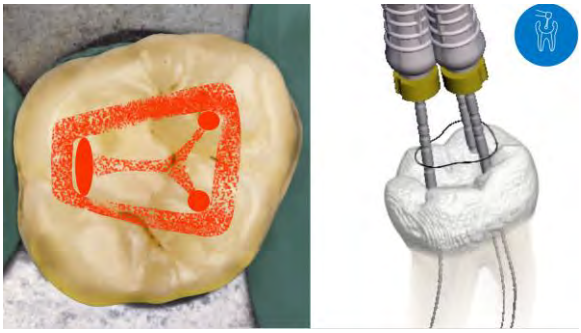

In the image above, the diagram of the pulpal floor (dentinal map) is superimposed on the molar tooth gives an idea of where the outline needs to be.

Understanding where the floor of the pulp chamber is critical. Many iatrogenic errors occur when the clinician does not adequately determine the depth of the chamber.

Digital radiography systems often have software with measurement tools which can be utilized to determine the depth of the chamber.

For those without, there are some ways using film to get similar information.

Periapical radiographs are frequently created with a vertical angulation that prevents assessing the true occluso-apocal dimensions of the tooth. Even when made with a paralleling kit, there is some distortion of this dimension (especially in the maxillary teeth).

To avoid perforation on access, the bite wing radiograph gives a better assessment of the dimensions of the pulp chamber.

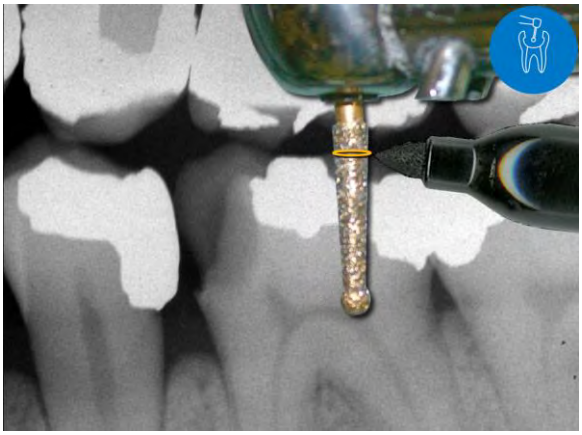

Here are some steps for estimating pulp chamber depth using a traditional film bitewing x-ray.

1. Assess pulp chamber height.
2. Choose largest pulp space.
3. Identify occlusal reference point.
4. Place bur in handpiece and hold up to bitewing X-ray with the tip of the bur below the pulp chamber roof.
5. Visualize an occlusal reference point on the shaft of the bur.
6. Stop cutting when the bur depth reaches the marked point on the shaft of the instrument.

Coronal preflaring provides the clinician with several advantages. It should be understood that as curved canals are enlarged, the distance from the occlusal or incisal reference point to the apical terminus decreases. Preflaring reduces this curvature before the primary working length is obtained and so makes the measurement more accurate. Preflaring also facilitates placing instruments in the canal by allowing better visibility of the orifice.

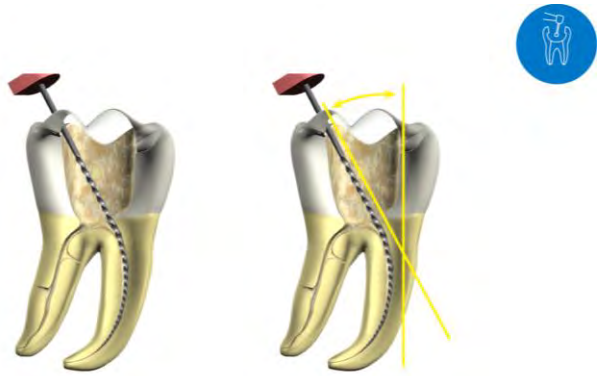

The three phases of access preparation are:

- Penetration
- Enlargement
- Refinement

Access

Here are the basic steps for an endodontic access preparation:

- Advance the initial bur toward most prominent pulp horn or largest canal.
- Feel the bur "Drop In"
- Use the bur in a withdrawing motion, cutting on the out-stroke.
- Visualize the floor of the pulp chamber and extrapolate occlusally.
- Locate the orifices with a DG16.

When accessing multi-rooted teeth, always look for the dentinal map. The change in color of the dentin will indicate canal locations. Also note that the floor of the chamber has a stippled texture and an organic look that distinguishes it from the prepared dentinal walls.
Magnification and illumination are a must when accessing a tooth. After the initial unroofing of the chamber, careful drying (without blowing compressed air into the canals) will many times reveal the canal orifices. Sometimes the accumulation of dust in the orifices will be the giveaway to it's location.

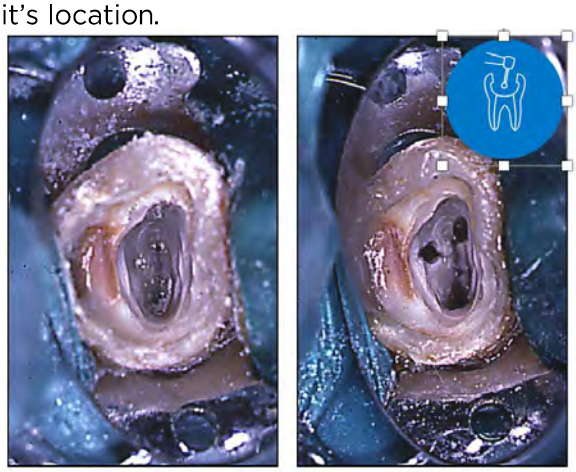

REFERENCES:

Gutmann, James L., and Paul E. Lovdahl. Chapter 8. Problem Solving in Endodontics: Prevention, Identification, and Management. 5th ed. St. Louis: Elsevier, 2011.

Vertucci, Frank J. "Root canal anatomy of the human permanent teeth." Oral surgery, oral medicine, oral pathology 58.5 (1984): 589-599.

Castellucci, Arnaldo. “Access Cavity and Endodontic Anatomy.” Endodontics, vol. 1, Il Tridente, Florence, 2004.

Vertucci, Frank J, Haddix, James E. “Tooth morphology and access cavity preparation.” Hargreaves, Kenneth M., Cohen, Stephen (eds). Cohen’s Pathways of the Pulp, 10th edition, Mosby Elsevier, St. Louis, MO, 2011.

Deutsch, Allan S., and Barry Lee Musikant. "Morphological measurements of anatomic landmarks in human maxillary and mandibular molar pulp chambers." Journal of endodontics 30.6 (2004): 388-390.

Krasner, Paul, and Henry J. Rankow. "Anatomy of the pulp-chamber floor." Journal of endodontics 30.1 (2004): 5-16.

De Pablo, Ó. V., Estevez, R., Sánchez, M. P., Heilborn, C., & Cohenca, N. "Root anatomy and canal configuration of the permanent mandibular first molar: a systematic review." *Journal of endodontics* 36.12 (2010): 1919-1931.

Hülsmann, Michael et al. “Problems in Determining Endodontic Working Length.” Problems in Endodontics: Etiology, Diagnosis, and Treatment, Quintessence, London, 2009.

Morgan, Leslie F., and Steve Montgomery. "An evaluation of the crown-down pressureless technique." Journal of endodontics 10.10 (1984): 491-498.

Ibarrola, Jose L., et al. "Effect of preflaring on Root ZX apex locators." Journal of endodontics 25.9 (1999): 625-626.

Shaping with WaveOne Gold

In endodontic files, there are a number for factors which play an important role in the performance (effectiveness & safety) of a given file.
These include:

- Design of the tip
- Shape of the cross-section
- Type of the lands
- Instrument taper
- Pitch of the flutes

One other major factor is the composition of the metal used in the manufacturing of the instruments.

For years, most endodontic instruments were made from stainless steel. In the late 1950s and early 1960s nickel and titanium were combined into an alloy which was called Nitinol. NiTi as it has come to be called was invented by navel scientists looking for a material that was intended originally as a bomb casing. The material showed promise in other areas due to its flexibility and strength. But it would not be until the 1980's when researchers began to look at it for endodontic files. The first widely adopted NiTi files were the ProFile instruments. These were introduced in the 1990s.

Pictured here on the left are the original ProFile Series 29 instruments as they looked when introduced in the 1990s. On the right are the WaveOne Gold instruments.

Shaping with WaveOne Gold



Recent research and development has led to the introduction of effective reciprocating files. Physically, these are similar to other NiTi instruments but their application is a unique characteristic that warrants further discussion.

Nickel titanium (NiTi) is a shape memory alloy also commonly referred to by the name, Nitinol. The material, if deformed while cool, returns to its undeformed shape when warmed.

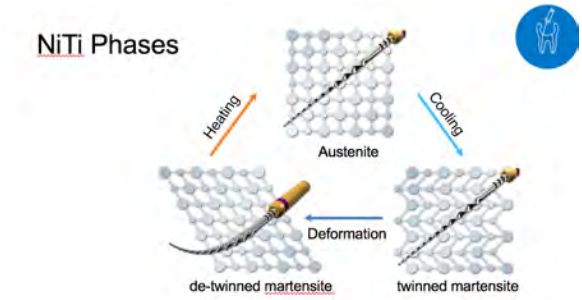

In the last few years, standard NiTi has been further transformed through additional treatments. Proprietary processing via the application of exact levels of heat over very specific periods conditions the metal. This processing leaves a thin oxide layer on the NiTi which gives it a gold or blue color depending upon the heat/time variables.
While NiTi is strong and flexible it still wears out. There are several factors that contribute to the length of a NiTi instrument's useful life. These include:

- Cyclic Fatigue
- Torsional Resistance
- Cutting Efficiency
- Corrosion
- Sterilization

Cardinal Rules - Straight Line Access

There are a number of rules which apply regardless of the NiTi instrumentation system being used.
These include:

- Creating straight line access
- Create and maintain a glide path and patency
- Use abundant, effective irrigants
- Using a light touch
- Limiting the amount of time any instrument is engaging the canal walls.
- Clean and inspect the file after each pass

Cardinal Rules - Instrumentation Time

A good rule is to never leave any instrument in the canal longer than 10 seconds… no matter how well it is progressing. In place of keeping time, another good technique is to limit the time an instrument is engaged in the canal by limiting the number of “pecks” or insertions to just three per pass. Each “peck” is a gentle movement coronally and only engages a millimeter or two before backing up a few millimeters. This motion technique generally provides a good level of efficiency while still being safe.

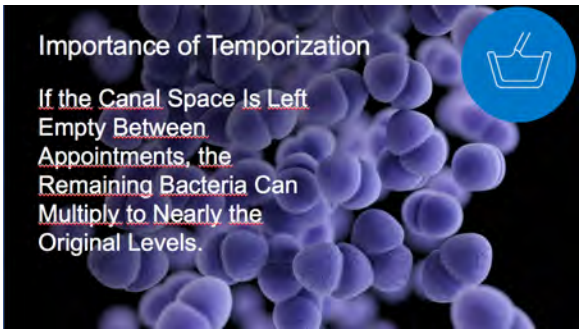

If the canal space is left empty between appointments, the remaining bacteria can multiply to nearly the original levels.

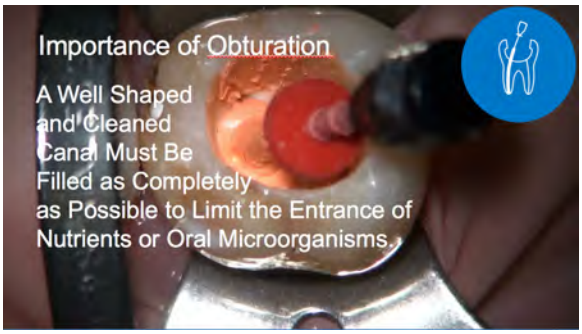

A well-shaped and cleaned canal system should create the best possible stage for the body's immune system to encourage healing. The space should be filled as completely as possible in order to limit the entrance of nutrients or oral microorganisms. While no established techniques for root canal filling create a perfect coronal, lateral and apical seal, many techniques offer high potential for success.

A glide path is generally considered a smooth radicular passage from the canal orifice down to the apex of the root canal. This is achieved when the file creating it can enter from the orifice and follow the smooth canal walls uninterrupted to the terminus. This confirms that there is a pathway for rotary instruments to passively follow in the canal.

When determining canal shape and working length measurements the hand file is still an important player. Curved hand files and kinked hand files each have a usefulness in certain situations. When there is a suspicion of a tight apical curvature, a carefully manipulated hand file can yield important insights into the anatomy being faced.

The file on the top of the image above has been kinked. There are basically two straight sections (the primary shaft attached to the handle and the apical segment) and there is a small bend, or kink, in the shaft. Files kinked like this have limited usefulness and usually result after attempts to pre-curve a file using the fingers alone.
The file on the bottom has been pre-curved anatomically using a bending instrument. There is a continuous smooth curvature extending from the shaft of the instrument through to the tip. This instrument is pre-curved properly and allows the instrument to work while minimizing the likelihood of canal transportation.

Shaping with WaveOne Gold

The initial canal space does not have smooth walls. Creation of the glide path is necessary to allow larger shaping files a smoother track as they progress into the canal. The WaveOne Gold Glider reduces the irregularities as it makes its way. In this slide, the dashed lines in the second and third show the desired, smooth glide path. The fourth image shows the now-smooth glide path and the dashed lines indicate the original canal.

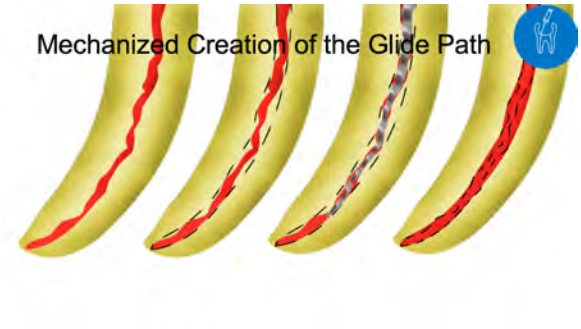

The WaveOne Gold Glider has the following specifications:

- Semi active tip, size ISO 015
- Progressive taper from 2% to 6%
- Parallelogram shaped cross-section
- Variable pitched helical angles
- Same reciprocating motion as WaveOne Gold shaping instruments.
- Made from NiTi plus a proprietary gold thermal treatment.

Shaping with WaveOne Gold

The sequence steps for use of the WaveOne Gold Glider is as follows:

- Obtain straight line access
- Establish working length with an apex locator, alone or in combination with a radiograph.
- Confirm patency with a .10 K-file and verify a smooth, reproducible glide path.
- Irrigate
- Use WaveOne Gold Glider in one or more passes until the full working length is reached.

There are a handful of key principals which support the WaveOne Gold concept. These include:

- Reciprocation reduces stresses along the length of the file because of the release of tension during the "back" motion.
- Apical constrictions are generally small as shown by recent research.
- Bacteria don't travel far into apical dentinal tubules which we know from research.
- Sufficient taper allows for good irrigation. The apical extent of the canal space must allow close penetration of an irrigating needle.
- Better metallurgy improves performance. The "Gold" process produces a more flexible instrument while maintaining strength.

Shaping with WaveOne Gold



WaveOne Gold has four file sizes.
The Primary has a 25 tip and is used in all cases.
The Small is used when the Primary does not reach working length. It is a 20 at the tip.
The Medium and Large have 35 and 45 tips respectively.
Each of the instruments comes in a pre-sterilized blister pack and are ready to use right out of the package. These are considered single-patient-use instruments and should never be re-sterilized.
Sterilization will cause the plastic part of the handle to expand and be unusable.
The handle length is 11mm.



The cross-section has been particularly optimized to enhance the cutting efficiency while maintaining other benefits.
Unique cutting points enable the file to minimize any screwing effect.

Shaping with WaveOne Gold

The tip of the WaveOne Gold instrument is considered semi-active… not as aggressive as some other tips available. This is slightly modified from the original WaveOne. Those instruments had a modified-guiding tip.



The DFU sequence begins (as all instrumentation techniques) with a small hand file to scout the canal space.
Irrigation, recapitulation and re-irrigation is done after every instrument.
The WaveOne Gold Glider is used to create the glide path.

The WaveOne PRIMARY is used in most cases. Let the file progress a few millimeters each time. Remove it, clean off the debris and inspect the file each time.
Irrigation, recapitulation and re-irrigation is done again.
Re-insert the file and allow it to progress a few millimeters further in the space.
Irrigation, recapitulation and re-irrigation is done again.
Re-insert the file. Generally three passes, with three engaging strokes or wave are needed to reach length in most canals.
Inspect the flutes and gauge the canal space to determine if a large WaveOne Gold is necessary.

Shaping with WaveOne Gold

If the WaveOne Gold Primary has difficulty progressing, the canal space may be small and require stepping down in size to the WaveOne Gold Small file

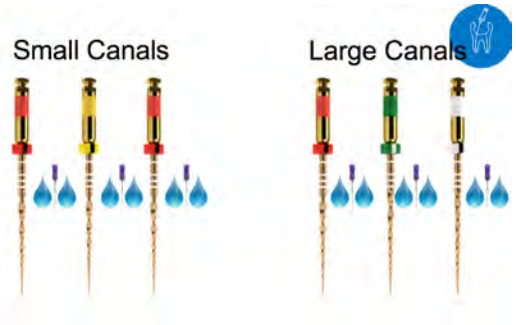

Regardless of the size of the initial canal, the PRIMARY is the first file in.
In situations where the PRIMARY does not progress, the SMALL is used. After the SMALL reaches length the clinician can go back to the PRIMARY where appropriate.

In situations where the PRIMARY easily goes to length and gauging indicates the canal has an apex larger than a 25, the MEDIUM is taken to length. In cases where the gauging indicates that the apex is larger than a 35, the LARGE is taken to length.

REFERENCES:

Ullmann, Cheryl J., and Ove A. Peters. "Effect of cyclic fatigue on static fracture loads in ProTaper nickel-titanium rotary instruments." Journal of endodontics 31.3 (2005): 183-186

Kazemi, Reza B., Evert Stenman, and Larz SW Spångberg. "The endodontic file is a disposable instrument." Journal of endodontics 21.9 (1995): 451-455.

Ametrano, G., et al. "Effects of sodium hypochlorite and ethylenediaminetetraacetic acid on rotary nickel–titanium instruments evaluated using atomic force microscopy." International endodontic journal 44.3 (2011): 203-209.

Roland, David D., et al. "The effect of preflaring on the rates of separation for 0.04 taper nickel titanium rotary instruments." Journal of endodontics 28.7 (2002): 543-545.

Berutti, Elio, et al. "Influence of manual preflaring and torque on the failure rate of ProTaper rotary instruments." Journal of endodontics 30.4 (2004): 228-230.

West, John. "Endodontic update 2006." Journal of esthetic and restorative dentistry 18.5 (2006): 280-300.

Berutti E, Cantatore G, Castallucci A, et al. “Use of Nickel-Titanium Rotary PathFile to Create the Glide Path: Comparison With Manual Preflaring in Simulated Root Canals.” Journal of Endodontics, Vol. 35, No. 3, (2009), pp. 408-412.

Patino PV, Biedma BM, Liebana CR, Cantatore G, Bahillo JG. The influence of a manual glide path on the separation rate of NiTi rotary instruments. J. Endod. 2005; 31:114–6.

Kim, Jin-Woon, et al. "Safety of the factory preset rotation angle of reciprocating instruments." Journal of endodontics 40.10 (2014): 1671-1675.

Kuttler, Yury. "Microscopic investigation of root apexes." The Journal of the American Dental Association 50.5 (1955): 544-552.

Marroquín, Benjamín Briseño, Mohammed AA El-Sayed, and Brita Willershausen-Zönnchen. "Morphology of the physiological foramen: I. Maxillary and mandibular molars." Journal of Endodontics 30.5 (2004): 321-328.

Bonilla, M., et al. “Incidence of Third Medial Canal in Mesial Roots of Lower Molars: A Micro CT Study”. Nova Southeast University. June 2010.

Love, Robert Matthew. "Regional variation in root dentinal tubule infection by Streptococcus gordonii." Journal of endodontics 22.6 (1996): 290-293.

Albrecht, Lynn J., J. Craig Baumgartner, and J. Gordon Marshall. "Evaluation of apical debris removal using various sizes and tapers of ProFile GT files." Journal of endodontics 30.6 (2004): 425-428.

“Cyclic Fatigue Test Of Single File System: WaveOne Gold”, Aranguren Jose; Bonilla Carmen; Bruder George; Perez Rigoberto & Hardigan Patrick. February 2015

Larsen, C. Michael, et al. "Cyclic fatigue analysis of a new generation of nickel titanium rotary instruments." Journal of endodontics 35.3 (2009): 401-403.

REFERENCES:

"Flexibility Test Of Single File System: WaveOne Gold". Aranguren Jose; Bonilla Carmen; Bruder George; Perez Rigoberto & Hardigan Patrick. February 2015.

"Evaluation of the Torsional Strength of a Single File System: WaveOne Gold". Aranguren Jose; Bonilla Carmen; Bruder George; Perez Rigoberto & Hardigan Patrick. February 2015.

"Evaluation of the Bending Test of a Single File System: WaveOne Gold" . Aranguren Jose; Bonilla Carmen; Bruder George; Perez Rigoberto & Hardigan Patrick. February 2015.

Irrigation

Research shows, regardless of the file system being used, up to 35% of the canal walls remain untouched by instruments. The root canal system must be thoroughly disinfected with irrigating solutions in order to achieve a successful outcome. The impact of not being thorough during the irrigation steps can be a negative one which can and will probably lead to case failures.

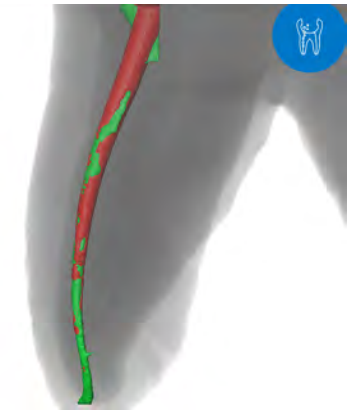

Pulp and Periapical tissues are irritated mechanically, chemically or by bacteria. The main mechanical irritant of the pulp is traumatic injuries leading to pulp exposure. The main mechanical irritant of periapical tissues is over instrumentation or overfilling. Chemical irritants of pulp tissue are medications or monomers placed in contact with the exposed dentinal tubules. Other major irritants of periapical tissues include forced irrigants or extruded filling materials. The most important irritants of the pulp and periapical tissues are bacteria. Experimental animal studies as well as human studies have shown that without bacteria - pulpal and periapical disease does not develop.

While infrequent, chemicals can irritate the periapical tissues when applied improperly. Forcing irrigants into periapical tissues can result in severe tissue damage at the end of the roots and severe hematoma and even life threating airway obstruction. It is a rare occurrence, and can be prevented by using side-vented needles and unforced irrigation of root canals during cleaning and shaping.

The response protocol for a hypochlorite accident includes, pain medication, antibiotics and regular follow-up. Referral to specialists may be necessary in some situations.

The most significant cause of inflammation is bacterial in origin. Bacteria present in dental decay are the main source of irritation of the dental pulp, its inflammation and necrosis and eventually formation of periapical diseases. The bacterial present in the dental decay consists of aerobic and anaerobic bacteria in the oral cavity. The character of bacterial flora changes after pulpal necrosis. In the root canal environment, the number of bacteria are reduced to few species and they are generally anaerobic in nature.

Interaction of bacteria present in root canals and the host cells in periapical tissues not only can result in formation of an acute abscess intra orally, it can also cause facial swelling.

The defensive forces of the body consists of non-specific reactions and specific immune responses. When a host has not been exposed to a foreign molecule (antigen) the host defends itself by non-specific reactions like inflammation and later on by immune reaction specific for that antigen. As egress of bacterial continues into the periradicular tissues, there is an ongoing war between the bacteria and defensive forces of the patient. The purpose of lesion formation is localizing the infection. When the defensive forces are overwhelmed an acute abscess with systemic symptoms develops.

Irrigation

One of the initial goals of root canal treatment is removing the disease tissue during cleaning, shaping and disinfecting of root canals.
The major root canal irrigants are:

- Water
- NaOCl
- EDTA
- CH

The Major medications used in the past and current medications are:

- Eugenol
- Formocresol
- Cresatin
- CMCP
- $Ca(OH)_2$

The purpose of filling root canals is to prevent recurrence of infection. Unfilled or poorly filled canals are prone to reinfection. Recontamination of the entire root canal system occurs rapidly if permanent coronal restorations are not placed right away. Anybody can do a great root canal, but it can be destroyed if a permanent restoration is not placed over it as soon as possible.

When root canals get infected bacteria enter the dentinal tubules (as shown above in the SEM of a tooth with necrotic pulp) and are protected if the dentinal tubules are not disinfected. Disinfection of the dentinal tubules occurs when the smear layer is removed and disinfected with proper irrigants and/or medications. The type of bacteria found in these tubules depends on the location and the depth of penetration of the microorganisms.

In addition, root canals are hardly round cylinders without ramifications. They are complicated systems with many isthmi between them and they contain lateral canals at different levels. These complicated system calls for complete cleaning with proper irrigants and complete obturation in three dimensions.

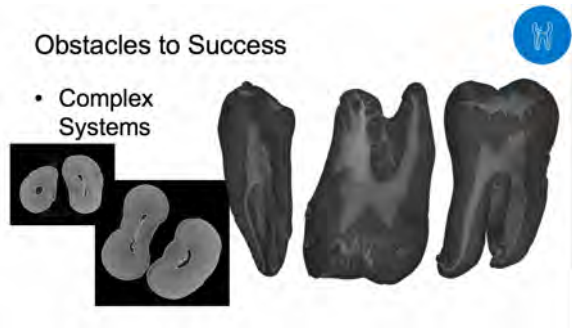

Studies have shown that current methods of cleaning and shaping root canals produce a smear layer that covers the instrumented walls. The smear layer consists of organic and inorganic substances that include fragments of odontoblastic processes, microorganisms and necrotic tissues. It consists of a superficial layer on the surface of the canal wall that averages between one and two µm in thickness, and a deeper layer packed into the dentinal tubules to a depth of up to 40 µm. Its penetration into the dentinal tubules is probably caused by capillary action generated between the dentinal tubules and the smear layer material. Since smear layer in infected root canals is contaminated, it should removed with proper irrigants.

Irrigation

There are three solutions that are the most widely used in endodontics for irrigation.
NaOCl is the most widely used.
It is well known to have the following beneficial properties:

- Dissolves organic tissue
- Kills microbes fast

NaOCl has also been shown to:

- Have no effect on inorganic tissue
- Weaken in contact with other materials
- Have a toxic/caustic effect on periapical tissue

The 2nd widely-used solution is EDTA. It is used to remove smear layer. While effective for smear layer removal, EDTA is limited.

- No bacteria killing effect.
- Does not dissolve soft tissue.
- May erode dentin with long exposures.

For endodontic purposes, CHX has gained popularity over the last several years as a final rinse.
It is well known to have the following beneficial properties:

- Kills bacteria (not fast)
- Improves long term dentin bonding to resins

CHX has its limitations:

- Does not dissolve tissue
- Does not disrupt biofilm

Proper tooth isolation is essential to all phases of root canal treatment, particularly patient protection and asepsis. Tooth isolation with a dental dam (also known as a rubber dam) using creative approaches to ensure complete coverage is sometimes required.

Various methods have been developed to make root canal irrigants more effective in removing debris and bacteria from the root canal system. These techniques can be classified into two broad categories: manual and mechanical agitation.

Manual agitation techniques include manipulation of irrigation solutions with hand files, brushes and gutta-percha points.

Mechanical agitation systems include sonic devices like the EndoActivator, ultrasonic needles and files and vacuum pressure (negative pressure) devices.
While some new devices both deliver and agitate the irrigation solutions, none have been widely adopted. Currently, the most common methods are via straight or side-vented needles.

Canal Size	Needle Size Reaching Apex
80	21 gauge
60	23 gauge
50	25 gauge
30	**30 gauge**
25	**30 gauge**
20	**30 gauge**
15	No Size Reached Apex

The apical extent of effectiveness of irrigation is a function of the depth of insertion of the needle and its size. Small bore needles are considered to be more effective than large ones.

Side vented needles are considered safer because there is less likelihood of extrusion of irrigant beyond the canal into the periapical region. Regardless of the type of needle being used always avoid binding the tip. Confirm that the needle can move freely before expressing any irrigants. Making a habit of only expressing solution on the outstroke can also reduce risk.

The EndoActivator used SONIC energy (default setting is approximately 10,000 cpm) to facilitate movement of irrigating solutions within the canal spaces.

Irrigation

The protocol for incorporating the EndoActivator into a typical treatment plan often begins with the final rinse.

- Prepare the canal to a fully tapered shape.
- Fill the pulp chamber with NaOCl, EDTA or other final rinse solution.
- Select the EndoActivator tip that fits loosely within 2mm of working length (Tips should not be taken closer than 2 mm from working length).
- Place the barrier sleeve over the drive to protect the handpiece.
- Attach the tip over the barrier.
- Place the attached tip into the prepared root canal.
- Press the On/Off button to activate.
- Use a pumping action to move the EndoActivator in short 2-3 ml vertical strokes for 30-60 seconds.
- Irrigate and use intracanal suction to remove loose debris.
- Repeat for each irrigant and each canal.

NaOCl during instrumentation is important to allow time for killing bacteria and to dissolve necrotic tissue from uninstrumented areas.
3% EDTA is used for removal of the smear layer. Exposure should be limited.

REFERENCES:

Peters, O. A., K. Schönenberger, and A. Laib. "Effects of four Ni–Ti preparation techniques on root canal geometry assessed by micro computed tomography." International endodontic journal 34.3 (2001): 221-230.

Kakehashi, S., H. R. Stanley, and R. J. Fitzgerald. "The effects of surgical exposures of dental pulps in germ-free and conventional laboratory rats." Oral surgery, oral medicine, oral pathology 20.3 (1965): 340-349.

Sundqvist, Göran. "Bacteriological studies of necrotic dental pulps." Umeå Univ., 1976.

Möller, Åke JR, et al. "Influence on periapical tissues of indigenous oral bacteria and necrotic pulp tissue in monkeys." European journal of oral sciences 89.6 (1981): 475-484.

Korzen, Barry H., Alvin Arlen Krakow, and Daniel B. Green. "Pulpal and periapical tissue responses in conventional and monoinfected gnotobiotic rats." Oral surgery, oral medicine, oral pathology 37.5 (1974): 783-802.

Bergenholtz, G. U. N. N. A. R. "Micro-organisms from necrotic pulp of traumatized teeth." Odontol Revy 25.4 (1974): 347-58.

Paterson, R. C. "Bacterial contamination and the exposed pulp." British dental journal 140.7 (1976): 231-236.

Hülsmann, M., and W. Hahn. "Complications during root canal irrigation–literature review and case reports." International endodontic journal 33.3 (2000): 186-193.

Torabinejad, Mahmoud, William C. Eby, and Irving J. Naidorf. "Inflammatory and immunological aspects of the pathogenesis of human periapical lesions." Journal of endodontics 11.11 (1985): 479-488.

Stashenko, Philip, et al. "Pathogenesis of induced rat periapical lesions." Oral surgery, oral medicine, oral pathology 78.4 (1994): 494-502.

Byström A, and Sundqvist G. "Bacteriologic evaluation of the efficacy of mechanical root canal instrumentation in endodontic therapy." European journal of oral sciences 89.4 (1981): 321-328.

Haapasalo, M., et al. "Irrigation in endodontics." British dental journal 216.6 (2014): 299-303.

Sjögren, U., et al. "The antimicrobial effect of calcium hydroxide as a short-term intracanal dressing." International endodontic journal 24.3 (1991): 119-125.

Madison, Sandra, Kimberly Swanson, and Susan A. Chiles. "An evaluation of coronal microleakage in endodontically treated teeth. Part II. Sealer types." Journal of endodontics 13.3 (1987): 109-112.

Swanson, Kimberly, and Sandra Madison. "An evaluation of coronal microleakage in endodontically treated teeth. Part I. Time periods." Journal of endodontics 13.2 (1987): 56-59.

Khayat, Akbar, Seung-Jong Lee, and Mahmound Torabinejad. "Human saliva penetration of coronally unsealed obturated root canals." Journal of endodontics 19.9 (1993): 458-461.

REFERENCES:

Magura, Mark E., et al. "Human saliva coronal microleakage in obturated root canals: an in vitro study." Journal of endodontics 17.7 (1991): 324-331.

Slutzky-Goldberg, Iris, et al. "Restoration of endodontically treated teeth review and treatment recommendations." International journal of dentistry 2009 (2010).

Nair, P. N. R. "On the causes of persistent apical periodontitis: a review." International endodontic journal 39.4 (2006): 249-281.

Gillen, Brian M., et al. "Impact of the quality of coronal restoration versus the quality of root canal fillings on success of root canal treatment: a systematic review and meta-analysis." Journal of endodontics 37.7 (2011): 895-902.

Guerra, Jose Arturo, Joseph E. Skribner, and Louis M. Lin. "Influence of a base on coronal microleakage of post-prepared teeth." Journal of endodontics 20.12 (1994): 589-591.

Jenkins, Stephen, et al. "Sealing ability of three materials in the orifice of root canal systems obturated with gutta-percha." Journal of endodontics 32.3 (2006): 225-227.

Torabinejad, Mahmoud, et al. "Clinical implications of the smear layer in endodontics: a review." Oral surgery, oral medicine, oral pathology, oral radiology, and endodontology 94.6 (2002): 658-666.

Davis, Stephen R., Stephan M. Brayton, and Melvin Goldman. "The morphology of the prepared root canal: a study utilizing injectable silicone." Oral surgery, oral medicine, oral pathology 34.4 (1972): 642-648.

Torabinejad, Mahmoud, et al. "Clinical implications of the smear layer in endodontics: a review." Oral surgery, oral medicine, oral pathology, oral radiology, and endodontology 94.6 (2002): 658-666.

Cengiz, T., B. O. Aktener, and B. Piskin. "The effect of dentinal tubule orientation on the removal of smear layer by root canal Irrigants." International endodontic journal 23.3 (1990): 163-171.

McComb, Dorothy, and Dennis C. Smith. "A preliminary scanning electron microscopic study of root canals after endodontic procedures." Journal of endodontics 1.7 (1975): 238-242.

Cameron, J. A. "The use of ultrasonics in the removal of the smear layer: a scanning electron microscope study." Journal of endodontics 9.7 (1983): 289-292.

Mader, Carson L., J. Craig Baumgartner, and Donald D. Peters. "Scanning electron microscopic investigation of the smeared layer on root canal walls." Journal of endodontics 10.10 (1984): 477-483.

Pashley, D. H. "Smear layer: overview of structure and function." Proceedings of the Finnish Dental Society. Suomen Hammaslaakariseuran toimituksia 88 (1991): 215-224.

Sim, T. P. C., et al. "Effect of sodium hypochlorite on mechanical properties of dentine and tooth surface strain." International endodontic journal 34.2 (2001): 120-132.

REFERENCES:

Clarkson, R. M., A. J. Moule, and H. M. Podlich. "The Shelf-Life of Sodium Hypochlorite Irrigating Solutions." Australian dental journal 46.4 (2001): 269-276.

Pişkin, Beyser, and Murat Türkün. "Stability of various sodium hypochlorite solutions." Journal of endodontics 21.5 (1995): 253-255.

Reeh, Ernest S., and Harold H. Messer. "Long-term paresthesia following inadvertent forcing of sodium hypochlorite through perforation in maxillary incisor." Dental traumatology 5.4 (1989): 200-203.

Çalt, Semra, and Ahmet Serper. "Smear layer removal by EGTA." Journal of endodontics 26.8 (2000): 459-461.

Torabinejad, Mahmoud, et al. "The antimicrobial effect of MTAD: an in vitro investigation." Journal of endodontics 29.6 (2003): 400-403.

Lee, L. W., W. H. Lan, and G. Y. Wang. "[A evaluation of chlorhexidine as an endosonic irrigant]." Journal of the Formosan Medical Association= Taiwan yi zhi 89.6 (1990): 491-497.

Southard, Steven R., et al. "The Effect of 2% Chlorhexidine Digluconate Irrigation on Clinical Parameters and the Level of Bacteroides gingivalis in Periodontal Pockets*." Journal of periodontology 60.6 (1989): 302-309.

Estrela, Carlos, et al. "Efficacy of sodium hypochlorite and chlorhexidine against Enterococcus faecalis: a systematic review." Journal of applied oral science 16.6 (2008): 364-368.

Torabinejad, Mahmoud, et al. "A new solution for the removal of the smear layer." Journal of endodontics 29.3 (2003): 170-175.

Gutmann, James L., and Paul E. Lovdahl. Chapter 8. Problem Solving in Endodontics: Prevention, Identification, and Management. 5th ed. St. Louis: Elsevier, 2011.

Chow, T. W. "Mechanical effectiveness of root canal irrigation." Journal of endodontics 9.11 (1983): 475-479.

Boutsioukis, Christos, et al. "Evaluation of irrigant flow in the root canal using different needle types by an unsteady computational fluid dynamics model." Journal of endodontics 36.5 (2010): 875-879.

Sedgley, C. M., et al. "Influence of irrigant needle depth in removing bioluminescent bacteria inoculated into instrumented root canals using real-time imaging in vitro." International endodontic journal 38.2 (2005): 97-104.

Cunningham, Walter T., and Aram Y. Balekjian. "Effect of temperature on collagen-dissolving ability of sodium hypochlorite endodontic irrigant." Oral surgery, oral medicine, oral pathology 49.2 (1980): 175-177.

Abou-Rass, Marwan, and Samuel W. Oglesby. "The effects of temperature, concentration, and tissue type on the solvent ability of sodium hypochlorite." Journal of endodontics 7.8 (1981): 376-377.

REFERENCES:

Cheung, G. S. P., and C. J. R. Stock. "In vitro cleaning ability of root canal irrigants with and without endosonics." International endodontic journal 26.6 (1993): 334-343.

Becker, Thomas D., and G. W. Woollard. "Endodontic irrigation." General dentistry 49.3 (2001): 272.

Stojicic, Sonja, et al. "Tissue dissolution by sodium hypochlorite: effect of concentration, temperature, agitation, and surfactant." Journal of endodontics 36.9 (2010): 1558-1562.

Guerisoli, D. M. Z., et al. "Evaluation of smear layer removal by EDTAC and sodium hypochlorite with ultrasonic agitation." International endodontic journal 35.5 (2002): 418-421.

Gutmann, James L., and Paul E. Lovdahl. Chapter 11. Problem Solving in Endodontics: Prevention, Identification, and Management. 5th ed. St. Louis: Elsevier, 2011.

Marending, M., et al. "Effect of sodium hypochlorite on human root dentine–mechanical, chemical and structural evaluation." International endodontic journal 40.10 (2007): 786-793.

Zehnder, Matthias. "Root canal irrigants." Journal of endodontics 32.5 (2006): 389-398.

Çalt, Semra, and Ahmet Serper. "Smear layer removal by EGTA." Journal of endodontics 26.8 (2000): 459-461.

Torabinejad, Mahmoud, et al. "The antimicrobial effect of MTAD: an in vitro investigation." Journal of endodontics 29.6 (2003): 400-403.

Regan, J. D., and A. A. Fleury. "Irrigants in non-surgical endodontic treatment." Journal of the Irish Dental Association 52.2 (2005): 84-92.
Review. (Baylor College of Dentistry, Dallas, Texas, USA)

Zehnder, Matthias. "Root canal irrigants." Journal of endodontics 32.5 (2006): 389-398.
Review. (University of Zurich Dental School, Switzerland)

Prado, M., Júnior, H. M. S., Rezende, C. M., Pinto, A. C., Faria, R. B., Simão, R. A., & Gomes, B. P.. "Interactions between irrigants commonly used in endodontic practice: a chemical analysis." *Journal of endodontics* 39.4 (2013): 505-510.

Obturation

The purposes of obturating the prepared root canal space are well founded in the contemporary art and science of endodontology.

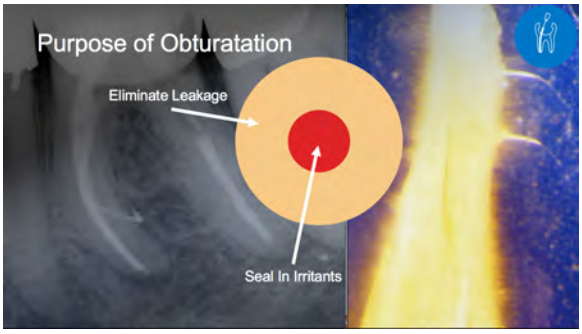

They can be simply stated as (1) to eliminate all avenues of leakage from the oral cavity or the periradicular tissues into the root canal system and (2) to seal within the system any irritants that cannot be fully removed during canal cleaning and shaping procedures. The rationale for these objectives recognizes that microbial irritants (microorganisms, toxins, and metabolites) along with products of pulp tissue degeneration are the prime causes for pulpal demise and its subsequent extension into the periradicular tissue. Failure to eliminate these etiologic factors and to prevent further irritation via continued contamination of the root canal system are the prime causes for failure with nonsurgical and surgical root canal treatment.

The importance of three-dimensional obturation of the root canal system cannot be overstated. However, the ability to achieve this goal is primarily dependent on the quality of the canal cleaning and shaping.

Root canal obturation is defined and characterized as the three-dimensional filling of the entire root canal system as close to the cemento-dentinal junction as possible

Obturation

Historically, gutta-percha has proven to be the material of choice for the successful filling of the canal from its coronal to apical extent. Although not the ideal filling material, it has satisfied the majority of tenets for an ideal root filling material. Disadvantages (i.e., lack of rigidity and adhesiveness, ease of displacement under pressure) do not overshadow its advantages.

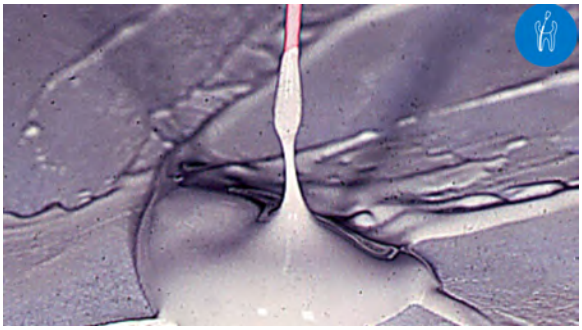

In light of the shortcomings indicated however, a sealer/cement is always used with the gutta-percha. Therefore, contemporary materials of choice are gutta-percha in conjunction with a sealer/cement. Neither substance alone enables canal obturation up to the standard of care regardless of the delivery system or compaction technique.

Contemporary practices of obturation favor some type of material softening to enable the movement of the material into the canal intricacies, including the dentinal tubules. However, even these achievements do not guarantee that an impervious seal of the root canal system will be established.

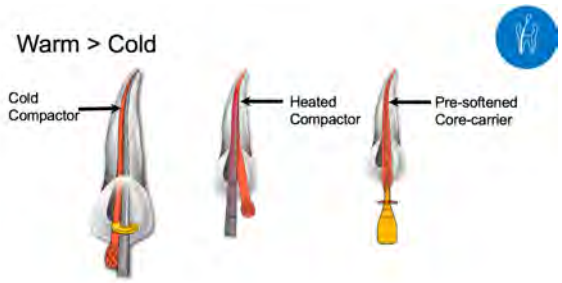

Obturation

While filling the entire root canal system is the major goal of canal obturation, a major controversy exists as to what constitutes the apical termination of the root canal filling material. Working length determination guidelines often cite the cementodentinal junction or apical constriction as the ideal position for terminating canal cleaning and shaping procedures and the position to which the filling material should be placed. It is important to note that the cementodentinal junction is not always the most constricted portion of the canal in the apical portion of the root.

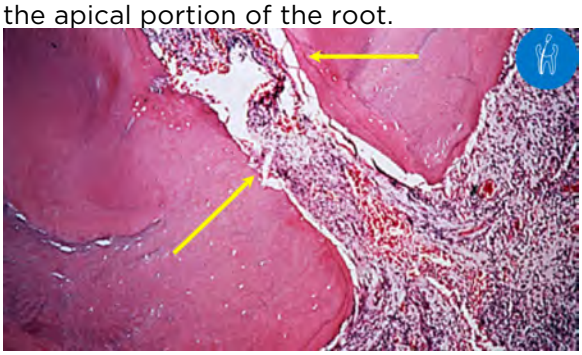

Gutta-percha points vary from brand to brand. Not only in sizing, but in consistency and handling properties. Note that both of the points are marked with red, indicating size 25. But both do not appear to be the same size in the body of the point. This is a critical point when working with instrument systems featuring multiple tapers.

Obturation

Gutta-percha points made via injection molding allows for consistent and precise shapes.
Micronized gutta-percha points have smaller particles and have a good heat transfer profile.



As shown in the thermal image above, the thermal profile of the Dentsply Sirona gutta-percha point shows transferred heat spreading from the point of contact with the heat carrier.
The heat profile temperature is as follows - from hottest to coolest is 1) White 2) Yellow 3) Pink 4) Red 5) Light Blue 6) Green 7) Blue 8 Black
The heat extension ≥4.0 mm and the Melt Flow is >0g/10min flow at 105°, 140° and 180°C. Increased heat extension and improved melt flow offers the opportunity to create a better 3D fill.

Obturation

The most important concept of the GuttaCore® techniqe is what is known as crosslinking. This is a proven scientific process with numerous applications the world over. With GuttaCore®, the process allows for the creation of a firm, non-melting, gutta-percha core.
At the molecular level, gutta-percha is polymer chain. The flowable gutta-percha of the GuttaCore® obturator is depicted with the blue molecules.

This image shows an artist's idea of the molecular view of a gutta-percha polymer chain. The crosslinkers bond the gutta-percha to provide the subtle strength and flexibility of the GuttaCore core.

This image below shows the heat profile of a GuttaCore carrier a full 10 seconds after being removed from the GuttaCore oven.



The thermal camera image on the right shows how the heat distribution is spread evenly over the length of the carrier. This is substantially different than the thermal profile of a gutta-percha point which only has transferred heat spreading from the point of contact with the heat carrier.
The heat profile temperature is as follows - from hottest to coolest is 1) White 2) Yellow 3) Pink 4) Red 5) Light Blue 6) Green 7) Blue 8 Black

Obturation

The clinical technique for GuttaCore carrier obturation begins with the insertion of a size verifier in a wet canal space to confirm the canal shape.

After the canal has been completely dried, a drop of sealer is to be used in each canal. A paper point is used as a paintbrush, delivering the sealer all the way around the canal.



A fresh, clean paper point is used even out the distribution of the sealer in the canal space and blot the excess sealer.

When the obturator has reached the appropriate temperature, (as indicated by the oven beep), carefully remove the obturator from the oven and place obturator into canal in one smooth continuous motion. Do not use excessive force. Pressure should follow obturator direction into the canal.

The most popular technique for removing the handle from the shaft is by bending to either side of the canal wall until the handle breaks loose from the stable portion in the canal space.

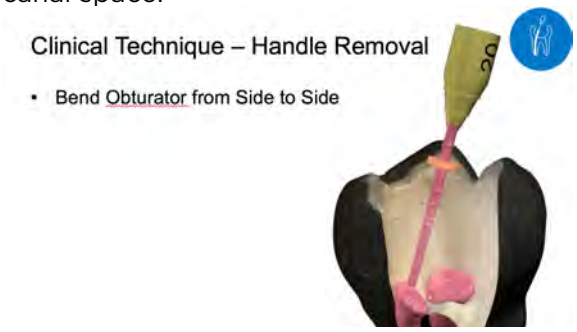

REFERENCES:

Naidorf, I. J. "Clinical microbiology in endodontics." Dental Clinics of North America 18.2 (1974): 329-344.

Buckley, Michael, and Larz SW Spangberg. "The prevalence and technical quality of endodontic treatment in an American subpopulation." Oral Surgery, Oral Medicine, Oral Pathology, Oral Radiology, and Endodontology 79.1 (1995): 92-100.

Gutmann, J. L. "Clinical, radiographic, and histologic perspectives on success and failure in endodontics." Dental Clinics of North America 36.2 (1992): 379-392.

Rud, Jorgen, J. O. Andreasen, and JE Möller Jensen. "A multivariate analysis of the influence of various factors upon healing after endodontic surgery." International journal of oral surgery 1.5 (1972): 258-271.

Sjögren, U. L. F., et al. "Factors affecting the long-term results of endodontic treatment." Journal of endodontics 16.10 (1990): 498-504.

Saunders, W. P., and E. M. Saunders. "Coronal leakage as a cause of failure in root-canal therapy: a review." *Dental Traumatology* 10.3 (1994): 105-108.

Ray, H. A., and M. Trope. "Periapical status of endodontically treated teeth in relation to the technical quality of the root filling and the coronal restoration." *International endodontic journal* 28.1 (1995): 12-18.

Gutmann, James L., et al. Chapter 1. Problem Solving in Endodontics: Prevention, Identification, and Management. 4th ed. St. Louis: Elsevier, 2006.

ØRstavik, D. A. G. "Materials used for root canal obturation: technical, biological and clinical testing." Endodontic topics 12.1 (2005): 25-38.

Whitworth, John. "Methods of filling root canals: principles and practices." Endodontic Topics 12.1 (2005): 2-24.

Huelsmann, M. "Endodontics in milk teeth-Current level." *GESUNDHEITSWESEN*. Vol. 70. No. 3. pp. 196-197; 2008.

Loest, Claus. "Quality guidelines for endodontic treatment: consensus report of the European Society of Endodontology." *International Endodontic Journal* 39.12 (2006): 921-930.

Huang, Tsui-Hsien, et al. "Root canal sealers induce cytotoxicity and necrosis." Journal of Materials Science: Materials in Medicine 15.7 (2004): 767-771.

Weller, R. N., et al. "Microscopic appearance and apical seal of root canals filled with gutta-percha and ProRoot Endo Sealer after immersion in a phosphate-containing fluid." International endodontic journal 41.11 (2008): 977-986.

Huffman, B. P., et al. "Dislocation resistance of ProRoot Endo Sealer, a calcium silicate-based root canal sealer, from radicular dentine." *International endodontic journal* 42.1 (2009): 34-46.

REFERENCES:

Balguerie, E., van der Sluis, L., Vallaeys, K., Gurgel-Georgelin, M., & Diemer, F.. "Sealer penetration and adaptation in the dentinal tubules: a scanning electron microscopic study." *Journal of Endodontics* 37.11 (2011): 1576-1579.

Al-Khatar N, Kunzelmann KH, Hickel R. Apical leakage of new root canal sealers. *Journal of Dental Research,* 1995, Vol. 74, No. 3, pp. 945-945)

Wang, Zhejun, Ya Shen, and Markus Haapasalo. "Dentin extends the antibacterial effect of endodontic sealers against Enterococcus faecalis biofilms." *Journal of Endodontics* 40.4 (2014): 505-508.

Pinna, Luigi, et al. "In vitro cytotoxicity evaluation of a self-adhesive, methacrylate resin–based root canal sealer." Journal of endodontics 34.9 (2008): 1085-1088.

Tanomaru-Filho, M., Jorge, É.G., Tanomaru, J.M.G. and Gonçalves, M.,. "Radiopacity evaluation of new root canal filling materials by digitalization of images." *Journal of Endodontics* 33.3 (2007): 249-251.

Evans, John T., and James HS Simon. "Evaluation of the apical seal produced by injected thermoplasticized gutta-percha in the absence of smear layer and root canal sealer." Journal of endodontics 12.3 (1986): 101-107.

Gutmann, J. L. "Adaptation of injected thermoplasticized gutta-percha in the absence of the dentinal smear layer." International endodontic journal 26.2 (1993): 87-92.

Gutmann, James L., et al. “Problems in root canal obturation “. Problem Solving in Endodontics: Prevention, Identification, and Management. 4th ed. St. Louis: Elsevier, 2006.

Keane, Kevin M., and Gerald W. Harrington. "The use of a chloroform-softened gutta-percha master cone and its effect on the apical seal." Journal of endodontics 10.2 (1984): 57-63.

Metzger, Zvi, Oded Assif, and Aviad Tamse. "Residual chloroform and plasticity in customized gutta-percha master cones." Journal of endodontics 14.11 (1988): 546-549.

Wu, Min-Kai, Paul R. Wesselink, and Richard E. Walton. "Apical terminus location of root canal treatment procedures." Oral Surgery, Oral Medicine, Oral Pathology, Oral Radiology, and Endodontology 89.1 (2000): 99-103.

Mayne, John R., Stewart Shapiro, and Irving I. Abramson. "An evaluation of standardized gutta-percha points: Part I. Reliability and validity of standardization." Oral surgery, oral medicine, oral pathology 31.2 (1971): 250-257.

Restoration

There are a number of factors which can impact the restoration of an endodontically treated tooth.
The clinician must consider:

- Vital vs. Non-Vital
- Direct vs. Indirect
- Post vs. No Post

A non-vital tooth will experience a denaturation of collagen fibers occurs after the root canal treatment. This has an influence on adhesion properties as all current adhesive systems rely on adhesion to collagen.



It is important to preserve the marginal crest as a structure that can compensate for the stresses generated by occlusal chewing forces.

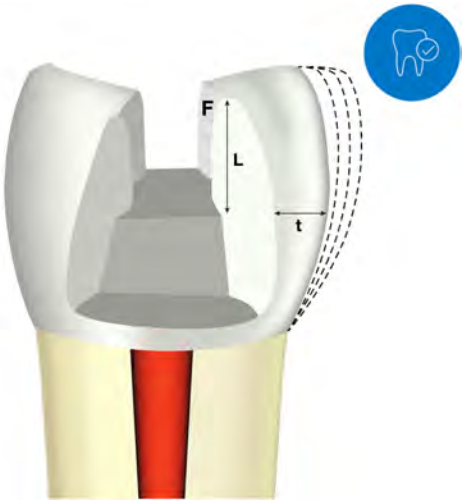

Research has shown that an access cavity will not reduce the stiffness of a tooth very much. On the other hand, an MOD cavity (with the loss of both marginal ridges) will have an impact on the residual strength of the tooth and on the restorative decision that has to be taken.

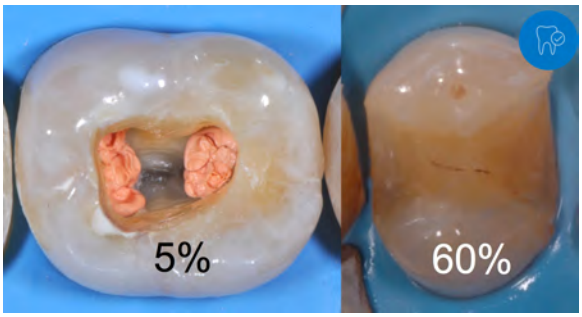

Guidelines for post placement are lacking in respect of the amount of tooth structure, particularly in cases in which 50% of coronal structure is preserved. Based on the evidence from reviews of previous papers, root filled premolars and molars with limited tissue loss can be restored without posts, particularly when total coverage is planned. However, when no cusp protection is provided, post placement appears to be beneficial in premolars.

Loss of vitality followed by proper endodontic therapy proved to affect tooth biomechanical behavior only to a limited extent. Conversely, tooth strength is reduced in proportion to coronal tissue loss, due to either caries lesions or restorative procedures. Therefore, the best current approach for restoring endodontically treated teeth seems to be: (1) Minimize tissue sacrifice, especially in the cervical area so that a ferrule effect can be created, (2) Use adhesive procedures at both radicular and coronal levels to strengthen remaining tooth structure and optimize restoration stability and retention, and (3) Use post and core materials with physical properties close to those of natural dentin, because of the limitations of current adhesive procedures.

Advantages of fiber posts include dentin like elasticity, reduced risk of catastrophic failure and superior aesthetic properties, owed to their translucency.

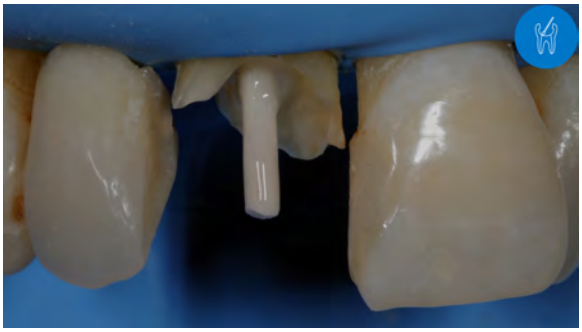

However, there also are some challenges around fiber posts, especially around their adhesive placement:
A key issue is that separate light curing of the adhesive may impair post fit:

- Due to adhesive pooling at the bottom of the post space.
- Due to alteration of post space geometry through adhesive film thickness (vertical walls).

Light curing of the adhesive in the depth of a canal / post space prior to resin cement application may be difficult. It is not exactly known how much of the light applied will arrive in the depth and thus how thorough the adhesive will polymerize.
Some research shows that the apical portion was reached by a significantly lower amount of light. Therefore, the light intensity at the deepest level of the canal may be insufficient to induce proper polymerization.
For that reason, it is desirable to place posts with an adhesive that has the ability to thoroughly self-cure in areas where light triggered polymerization is impaired.

Prime&Bond, when mixed with sodium tetraphenylborate (from the SCA = Self-Cure Activator) forms triphenylborane triggering the chemical polymerization. Additionally, Prime&Bond must be mixed with the SCA whenever it is to be used in conjunction with a dual-cure resin cement such at Calibra or CoreX Flow.

In order to achieve reliable adhesion, etching is the state-of-the-art method.

This picture above shows a cavity that is filled up with blue phosphoric acid etching gel. For this material, standard etching times are 15 seconds for dentin and 30 seconds for enamel. It is then rinsed off with water spray.
Self-etch adhesives are a more recent development. They exhibit an inherent acidity that make the application of a separate etching gel obsolete.
Universal-Etch adhesives are the most recent development. These adhesives can be used either way - in an etch & rinse sequence or in a self-etch technique - or even in a combination of both which is called the “selective-etch technique“,. Prime&Bond Active belongs to this product category.

Dentin wetness is a common phenomenon and a challenge to any commercially available adhesive. Before an adhesive is applied, the surplus of water needs to be removed. There are various ways of drying a cavity: air syringe, suction or the blot drying technique. It is for that reason, that different dentists will always produce different drying results. Standardized wetness or dryness, respectively, is hard to achieve.
In addition, caries-affected dentin is significantly wetter than sound dentin.

The ideal adhesive will reliably bond to both wet and dry surfaces. In addition, it will have a low surface tension and be able to spread across the surface to minimize the risk of leaving un-wet areas.

Restoration

Traditional or regular composites are applied to dental cavities in 2 mm increments in order to keep contraction forces small during multi-layer light curing.

Newer bulk-fill composites work because they are adhesively bonded to multiple cavity walls. This keeps the composite from shrinking upon light-curing. The adhesive holds the composite in place and keeps it from shrinking.
SDR flow+ can be applied in 4 mm increments. SDR flow+ is suggested as a fast and simple approach for restoration of endodontic access cavities, which can easily reach a depth of 10 mm or more. In such cases, two rounds of SDR would be needed. The sequence would be:

- Application of Prime & Bond Active
- Light cure
- Application of 4mm of SDR,
- Light cure
- Application of 4mm of SDR
- Light cure
- Application of cap composite
- Light cure

There is evidence that as much as 37% percent of restorations placed are under-cured. Curing lights should be carefully chosen to provide enough power to fully reach deep endodontic access cavities.



Consideration should be given to the power of the unit itself, the distance needed to fully cure the material and the focus of the beam.

A cap composite is required on top of SDR flow+ in order to enhance abrasion resistance. The key considerations for choosing a cap composite are:

- Handling characteristics:
  - Some dentists prefer a firm-handling composite they can pack and sculpt.
  - Some dentists prefer a creamy-handling composite to spread and flow
- Simple shading system/chameleon effect
- Stain resistance
- Polishability

TPH Spectra offers dual viscosities - LV (low viscosity) and HV (high viscosity) versions.

Contact point creation is a critical aspect when placing posterior composite restorations. An open or improperly placed or shaped proximal contact can result in a fracture or food impaction which can lead to periodontal inflammation, bone loss and recurrent caries.
Highly effective separation forces will ensure predictable and tight contact point creation.

In the image above, note the minimal composite excess and restoration shape after the matrix system has been removed from the tooth as well as the natural ridge contour which is owed to the contour of the Palodent matrix band.

When 3 or 4 residual walls are present, a direct restoration without a fiber post can often be placed.

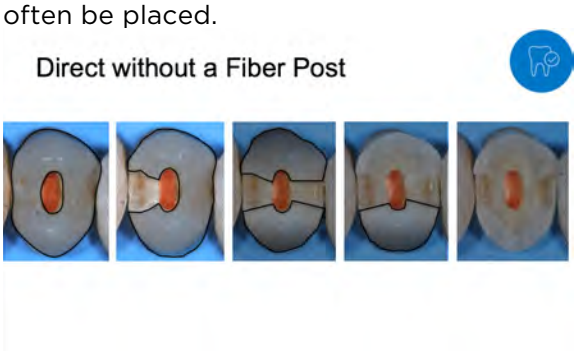

The purpose of a post is to keep the core in place against compressive forces and distribute stress along the axis of the tooth.
Metal posts, especially the prefabricated ones, can de-bond and cause fractures of the remaining tooth structure.

The ideal post should be elastic enough to follow the natural flexural movements of the tooth structure.
Metal posts offer a less-than favorable load distribution at the interface. This creates a stress concentration that can lead to fracture of the remaining tooth structure.
Fiber posts create a distribution of the stress between the post and the dentine, creating a favorable load distribution at the interface.

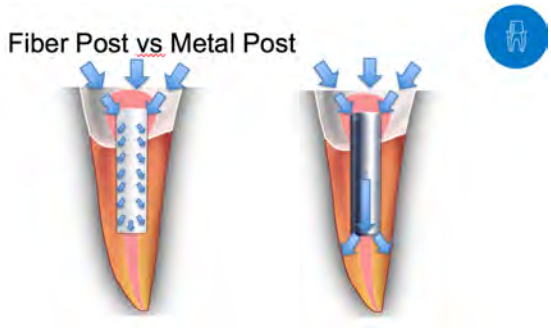

A fiber post should be placed whenever there is insufficient tooth structure to ensure retention for the core and “protect” from un-restorable fractures.

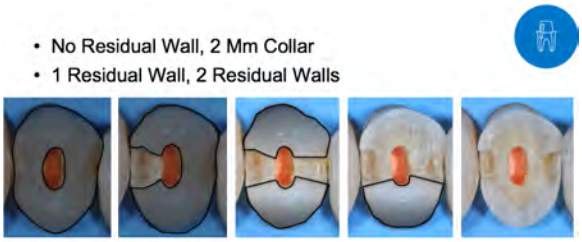

Fiber Post

Restoration

When evaluating restoration options, consider not only the number of residual walls, but also their "strength".

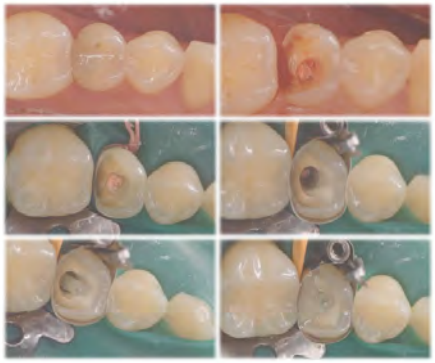

In this clinical case sequence shown above, a direct restoration is the first treatment option. However, thinking long term, a crown might be placed in future years. For this reason, a fiber post is placed to ensure retention for the core and "protect" from un-restorable fractures

When preparing for an indirect restoration, if possible, a uniform 2-mm circumferential ferrule should be provided.

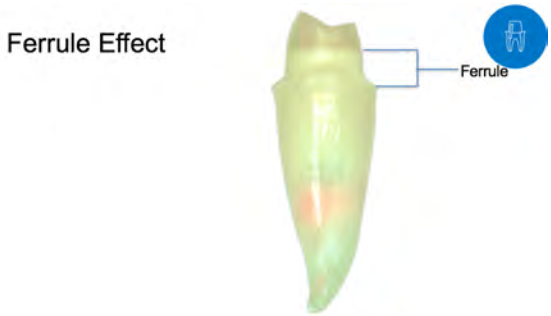

REFERENCES:

Ferrari, M., et al. "Collagen degradation in endodontically treated teeth after clinical function." Journal of dental research 83.5 (2004): 414-419.
REFERENCES:

Hashimoto, M., et al. "In vivo degradation of resin-dentin bonds in humans over 1 to 3 years." Journal of Dental Research 79.6 (2000): 1385-1391.

Castellucci, Arnaldo. Endodontics, vol. 1-3, Il Tridente, Florence, 1990.

Reeh, Ernest S., Harold H. Messer, and William H. Douglas. "Reduction in tooth stiffness as a result of endodontic and restorative procedures." Journal of endodontics 15.11 (1989): 512-516.

Assif, David, and Colin Gorfil. "Biomechanical considerations in restoring endodontically treated teeth." The Journal of prosthetic dentistry 71.6 (1994): 565-567.

Gutmann, James L. "The dentin-root complex: anatomic and biologic considerations in restoring endodontically treated teeth." The Journal of prosthetic dentistry 67.4 (1992): 458-467.

Loewenstein, W. R., and R. Rathkamp. "A study on the pressoreceptive sensibility of the tooth." Journal of dental research 34.2 (1955): 287-294.

Louca, Christos, Samuel W. Cadden, and Roger WA Linden. "The roles of periodontal ligament mechanoreceptors in the reflex control of human jaw-closing muscles." Brain research 731.1 (1996): 63-71.

Louca, Christos, et al. "The role of gingival mechanoreceptors in the reflex control of human jaw-closing muscles." Archives of oral biology 43.1 (1998): 55-63.

Mangani, F.,Sigalot, C.,Mancini, M., “Analysis of the mechanical resistance of crowns of posterior teeth treated endodontically after indirect adhesive restoration”. Abstract book from the International Congress of Italian Universities, Rome, 10-13 / 4-2003.

Salehrabi, Robert, and Ilan Rotstein. "Endodontic treatment outcomes in a large patient population in the USA: an epidemiological study." Journal of endodontics 30.12 (2004): 846-850.

Aurélio, I. L., et al. "Are posts necessary for the restoration of root filled teeth with limited tissue loss? A structured review of laboratory and clinical studies." International endodontic journal (2015).

Dietschi, Didier, et al. "Biomechanical considerations for the restoration of endodontically treated teeth: a systematic review of the literature—Part 1. Composition and micro-and macrostructure alterations." Quintessence International 38.9 (2007): 733-43.

Dietschi, Didier, et al. "Biomechanical considerations for the restoration of endodontically treated teeth: A systematic review of the literature, Part II (Evaluation of fatigue behavior, interfaces, and in vivo studies)." Quintessence International 39.2 (2008): 117-29.

REFERENCES:

Dammaschke, Till, et al. "Influence of coronal restorations on the fracture resistance of root canal-treated premolar and molar teeth: A retrospective study." Australian endodontic journal 39.2 (2013): 48-56.

Soares, Paulo Vinicius, et al. "Influence of restorative technique on the biomechanical behavior of endodontically treated maxillary premolars. Part I: fracture resistance and fracture mode." The Journal of prosthetic dentistry 99.1 (2008): 30-37.

Goracci C, Corciolani G, Vichi, A, Ferrari M: Light transmitting Ability of Marketed Fiber Posts. J Dent Res 87(12):1122-1126,2008

Ferrari, M., Cagidiaco, M. C., Goracci, C., & Polimeni, A. "XP Bond in Self-Cure Mode Used for Luting Porcelain Restorations: 4-year Recall." *World Journal of Dentistry* 1.2 (2010): 69-73.

Ito S, Saito T, Tay FR, Carvalho RM, Yoshiyama M, Pashley DH.: Water content and apparent stiffness of non-caries versus caries-affected human dentin. *Journal of Biomedical Materials Research Part B: Applied Biomaterials* 72.1 (2005): 109-116.

Ilie, Nicoleta, and Reinhard Hickel. "Investigations on a methacrylate-based flowable composite based on the SDR™ technology." *Dental Materials* 27.4 (2011): 348-355.

Price, Richard BT, Christopher M. Felix, and J. Marc Whalen. "Factors affecting the energy delivered to simulated class I and class V preparations." *Journal-Canadian Dental Association* 76.4 (2010): 233.

Rosenburg, Jeffrey M (2013). Dentistry Today. Making Contact: A Method for Restoring Adjacent Posterior Direct Resin.

Guzy, Gary E., and Jack I. Nicholls. "In vitro comparison of intact endodntically treated teeth with and without endo-post reinforcement." The Journal of prosthetic dentistry 42.1 (1979): 39-44.

Asmussen, Erik, Anne Peutzfeldt, and Thomas Heitmann. "Stiffness, elastic limit, and strength of newer types of endodontic posts." Journal of dentistry 27.4 (1999): 275-278.

Sorensen, John A., and James T. Martinoff. "Intracoronal reinforcement and coronal coverage: a study of endodontically treated teeth." The Journal of prosthetic dentistry 51.6 (1984): 780-784.

Duke, E. Steven. "New directions for posts in restoring endodontically treated teeth." Compendium of continuing education in dentistry (Jamesburg, NJ: 1995) 23.2 (2002): 116.

Sorrentino, Roberto, et al. "Three-dimensional finite element analysis of strain and stress distributions in endodontically treated maxillary central incisors restored with diferent post, core and crown materials." Dental materials 23.8 (2007): 983-993.

Akkayan, Begüm, and Turgut Gülmez. "Resistance to fracture of endodontically treated teeth restored with different post systems." The Journal of prosthetic dentistry 87.4 (2002): 431-437.

REFERENCES:

Ferrari, Marco, Alessandro Vichi, and Franklin Garcia-Godoy. "Clinical evaluation of fiber-reinforced epoxy resin posts and cast post and cores." Am J Dent 13. Spec No (2000): 15B-18B.

Maceri, Franco, Marco Martignoni, and Giuseppe Vairo. "Mechanical behaviour of endodontic restorations with multiple prefabricated posts: a finite-element approach." Journal of biomechanics 40.11 (2007): 2386-2398.

Maceri, Franco, Marco Martignoni, and Giuseppe Vairo. "Optimal mechanical design of anatomical post-systems for endodontic restoration." Computer methods in biomechanics and biomedical engineering 12.1 (2009): 59-71.

Salameh, Ziad, et al. "Effect of fiber post and resin core restorations on fracture resistance and failure pattern of endodontically-treated mandibular molars." Journal of endodontics 32 (2006): 752-755.

Sorrentino, R., Monticelli, F., Goracci, C., Zarone, F., Tay, F. R., & Ferrari, M., "Effect of post and core restorations on the resistance to fracture of endodontically treated maxillary premolars in different restorative systems." *J Adhes Dent* (2007).

Creugers, N. H., et al. "A 5-year prospective clinical study on core restorations without covering crowns." International journal of prosthodontics18.1 (2005): 40-1.

Grandini, Simone, et al. "Clinical evaluation of the use of fiber posts and direct resin restorations for endodontically treated teeth." International journal of prosthodontics 18.5 (2005).

Ferrari, M., et al. "Post placement affects survival of endodontically treated premolars." Journal of dental research 86.8 (2007): 729-734.

Tan, Philip LB, et al. "In vitro fracture resistance of endodontically treated central incisors with varying ferrule heights and configurations." The Journal of prosthetic dentistry 93.4 (2005): 331-336.